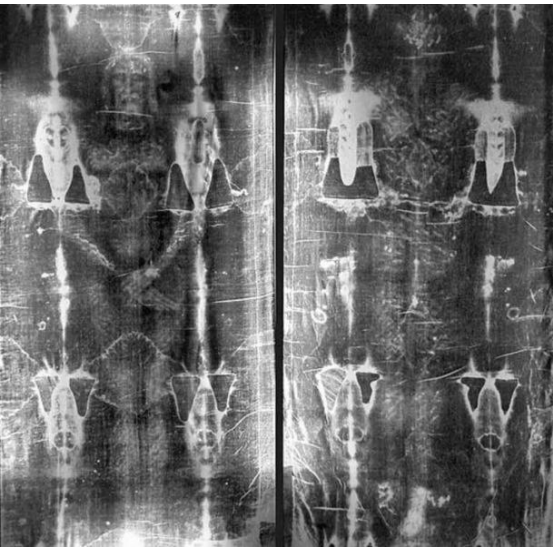

# 都靈聖殮布 Turin Shroud



Research by international experts in medicine, forensic science, anatomy, botany, textile science, optics, mechanics, archaeology.

I do not possess anything. All I have is only borrowed from God so that I may serve others. H. Anthony Chan [h.a.chan@ieee.org](mailto:h.a.chan@ieee.org)

Professor and Dean, School of Computing and Information Sciences, Caritas Institute of Higher Education, IEEE Fellow

# What is Turin Shroud 都靈聖殯布是什麼

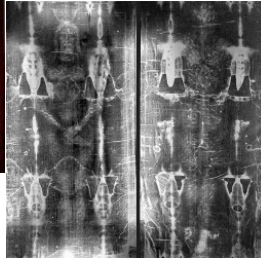
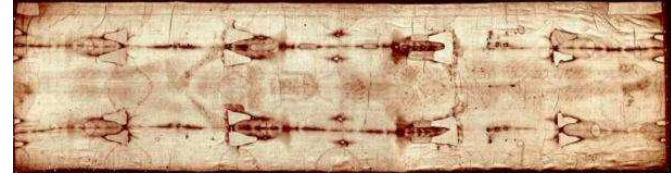
Arthur C. Lind and Mark Antonacci, "Hypothesis that explains the Shroud's unique blood marks and several critical events in the gospels," 2014



+



+



Negative  
底片

Flax linen    Bloodstains/clot    Image — surface, 3D info

高級亞麻布

arterial/venial; dead/live

血漬、血塊

動/靜脈、活人/死人

人像 — 最表面、三維訊息

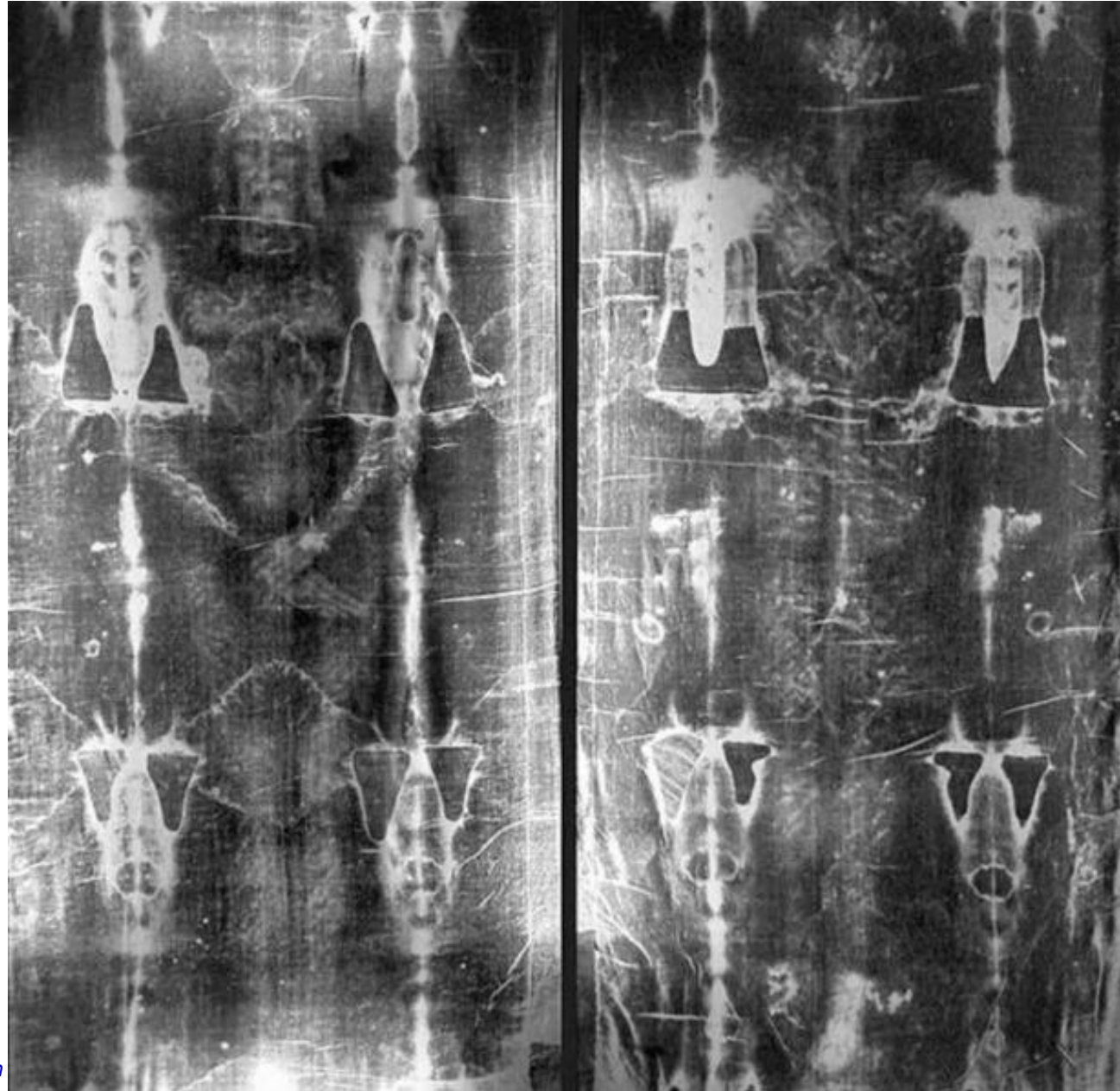


View from front and reverse side

從前面及底部看血漬

## Negative of photograph, 1898

- ◆ Secondo Pia discovered the negative of the photo he took shows a much clearer image of the body
- ◆ Image on the Shroud is therefore the negative of the body image
- ◆ Yet photography was only invented in 1839



*What I have is only borrowed from God so that I may serve others. H Anthony Chan*



Face many wounds and swollen, right eye almost closed



*What I have is only borrowed from God so that I may serve others. H Anthony Chan*

*March 20, 2025*

*Page 4*

# Face many wounds and swollen

*Sin with the 5 senses*  
*默想：用五官犯罪*

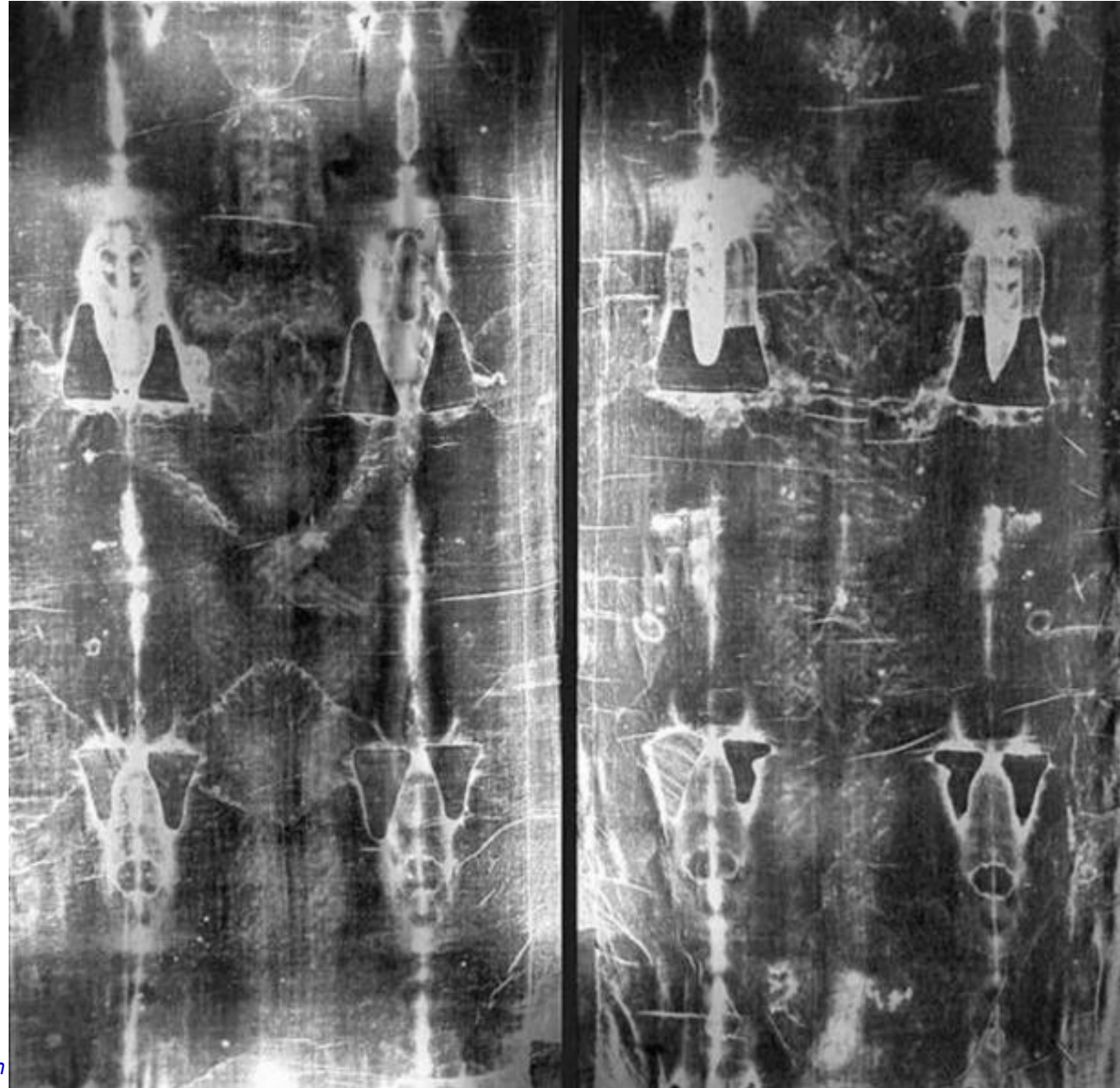
- ◆ one of the temple guards standing there struck Jesus and said, “Is this the way you answer the high priest?” (John 18:22)
- ◆ The men who held Jesus in custody were ridiculing and beating him. They blindfolded him and questioned him, saying, “Prophecy! Who is it that struck you?” (Luke 22:63-64)
- ◆ they came to him and said, “Hail, King of the Jews!” And they struck him repeatedly. (John 19:3)

*What I have is only borrowed from God so that I may serve others. H Anthony Chan*



## Severely scourged

- ◆ The photographic films shows that the entire body had been scourged: chest, back, waist, abdomen, hands, arms, buttocks, feet, thighs, calves are all whipped wounds
- ◆ Counted 370 scourges on front and back so far, estimate 600



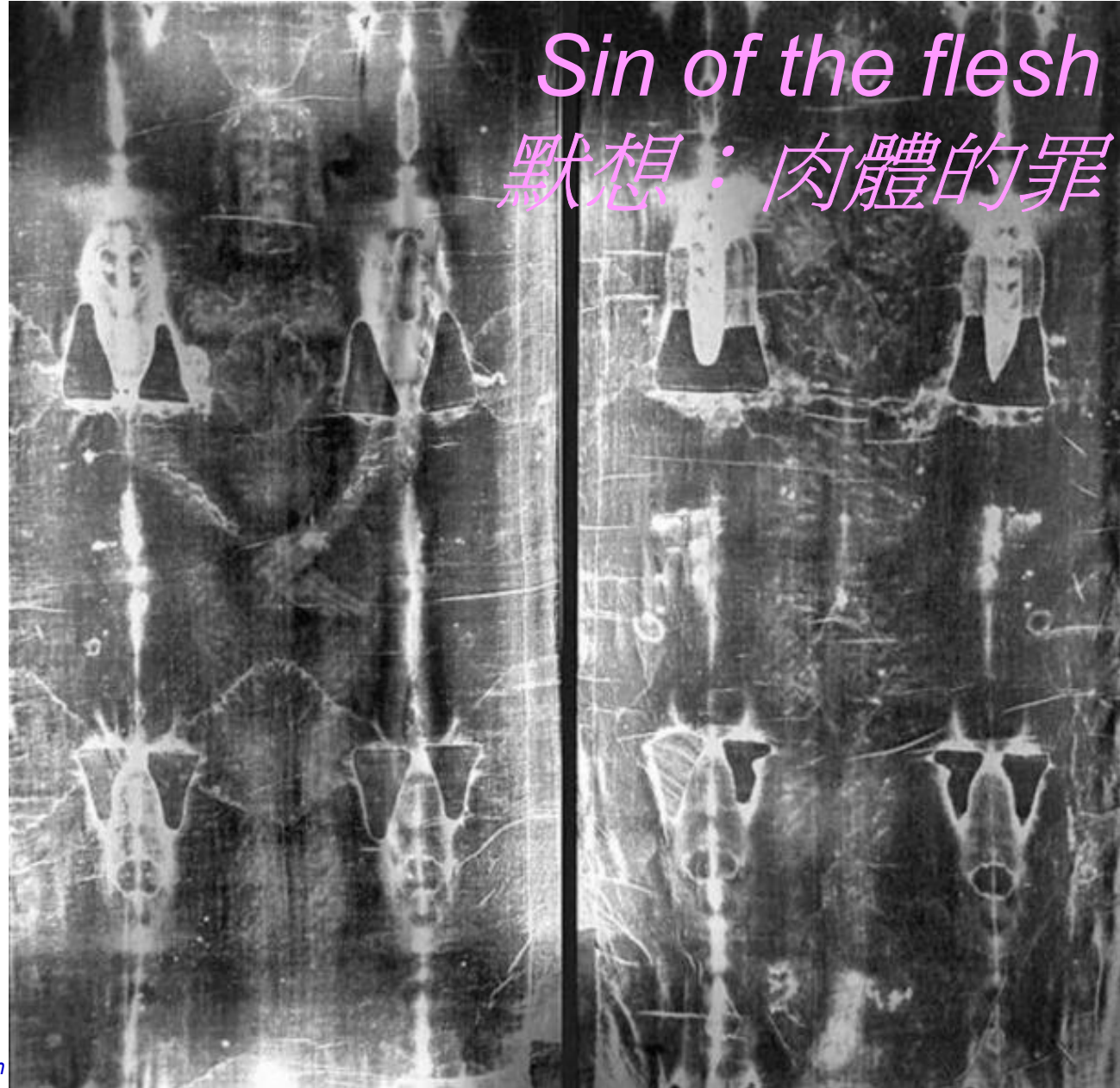
*What I have is only borrowed from God so that I may serve others. H Anthony Chan*



## Severely scourged

- ◆ The photographic films shows that the entire body had been scourged: chest, back, waist, abdomen, hands, arms, buttocks, feet, thighs, calves are all whipped wounds
- ◆ Counted 370 scourges on front and back so far, estimate 600


*Sin of the flesh*  
默想：肉體的罪



*What I have is only borrowed from God so that I may serve others. H Anthony Chan*

whip identified as one of those used by the Romans

- ◆ The Shroud shows that the body has been scourged with several different whips. The most obvious one has hard objects at the end to tear open the flesh with each strike.

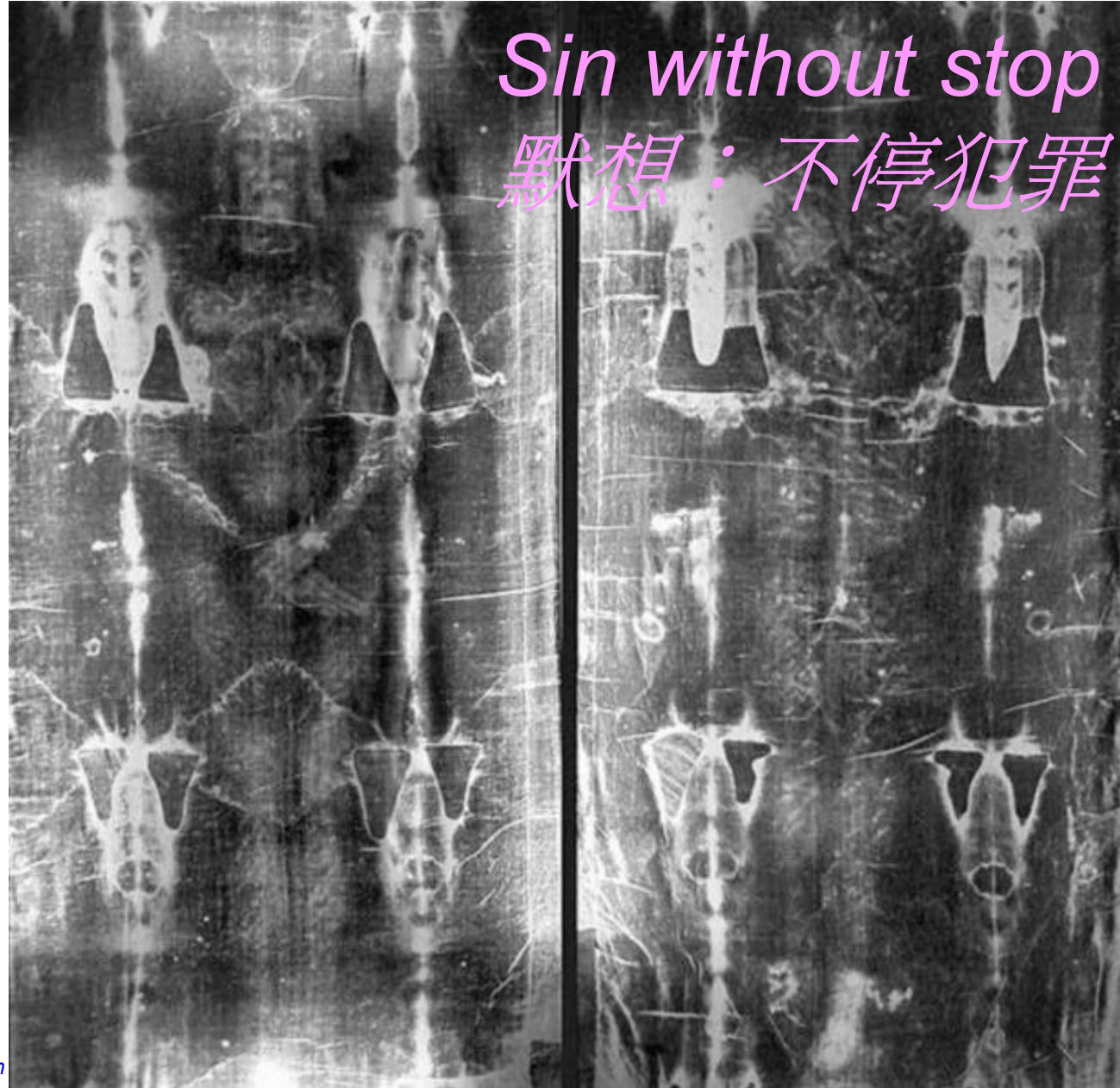




## Severely scourged

- ◆ The photographic films shows that the entire body had been scourged: chest, back, waist, abdomen, hands, arms, buttocks, feet, thighs, calves are all whipped wounds
- ◆ Counted 370 scourges on front and back so far, estimate 600

*Sin without stop*  
*默想：不停犯罪*



*What I have is only borrowed from God so that I may serve others. H Anthony Chan*

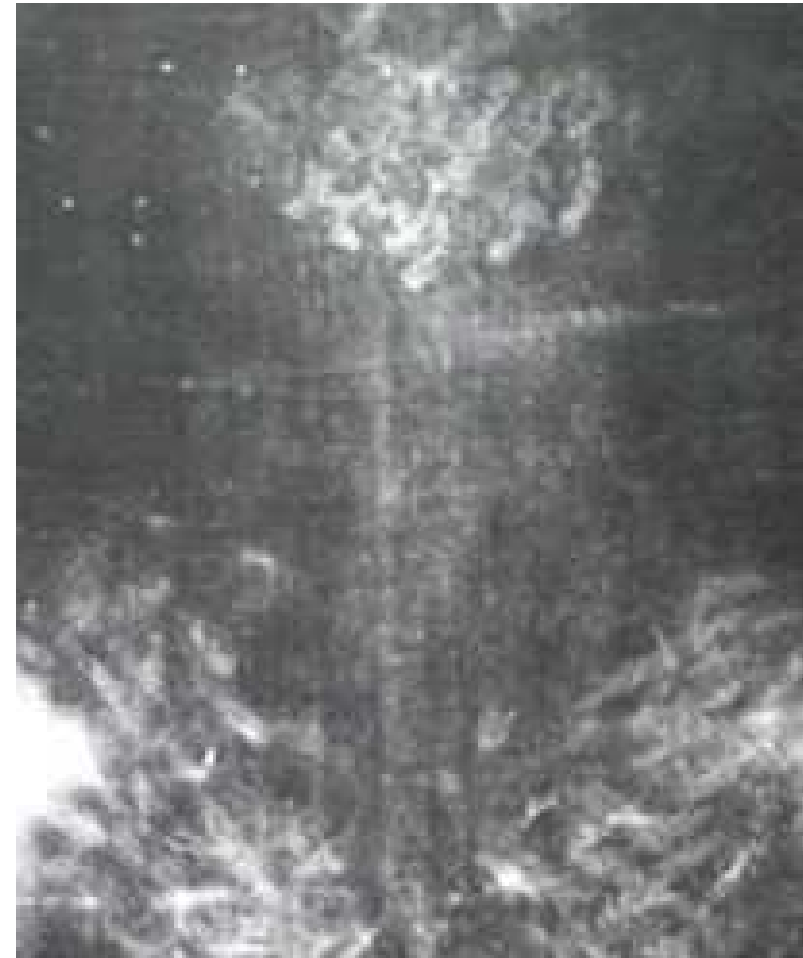
Front: forehead was pierced at multiple places

- ◆ Pilate also had an inscription written and put on the cross. It read, “Jesus the Nazorean, the King of the Jews.” Now many of the Jews read this inscription, because the place where Jesus was crucified was near the city; and it was written in Hebrew, Latin, and Greek. So the chief priests of the Jews said to Pilate, “Do not write ‘The King of the Jews,’ but that he said, ‘I am the King of the Jews.’” Pilate answered, “What I have written, I have written.” (John 19:19-22)



Back: top of head was pierced at many places

- ◆ 30 pierced wounds have been identified so far
- ◆ Crown of thorns was not a ring weaved of thorns, but covers the entire top of the head like a cap





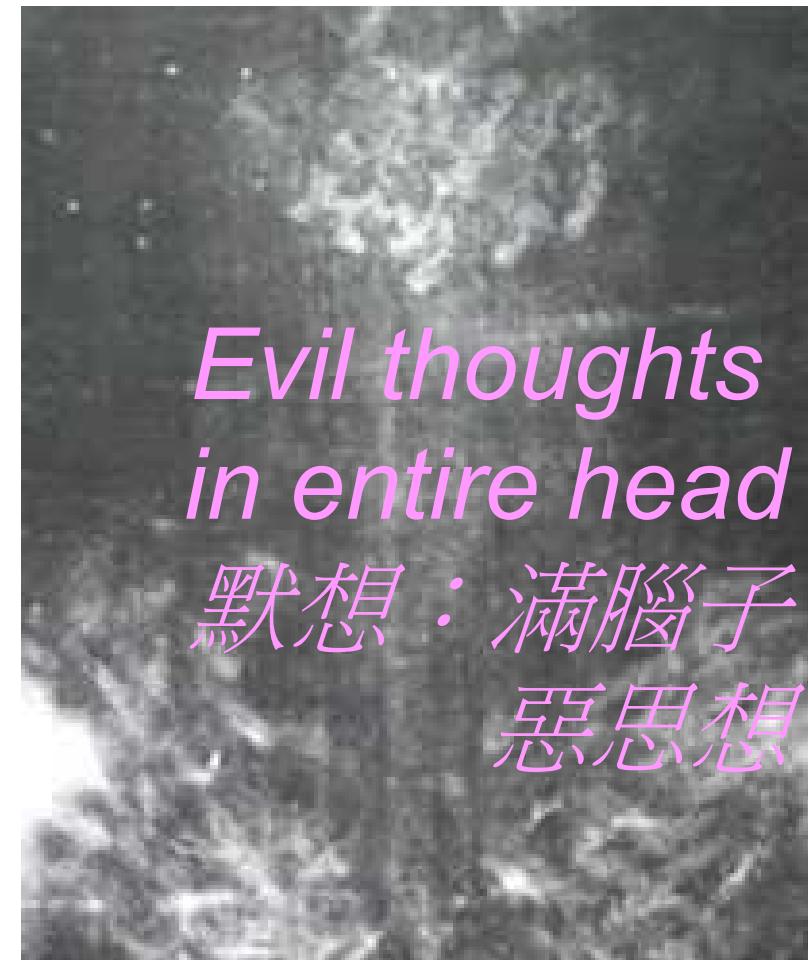## King of Jews!



- ◆ And the soldiers wove a crown out of thorns and placed it on his head, and clothed him in a purple cloak, and they came to him and said, “Hail, King of the Jews!” And they struck him repeatedly. (John 19:2-3)

Back: top of head was pierced at many places

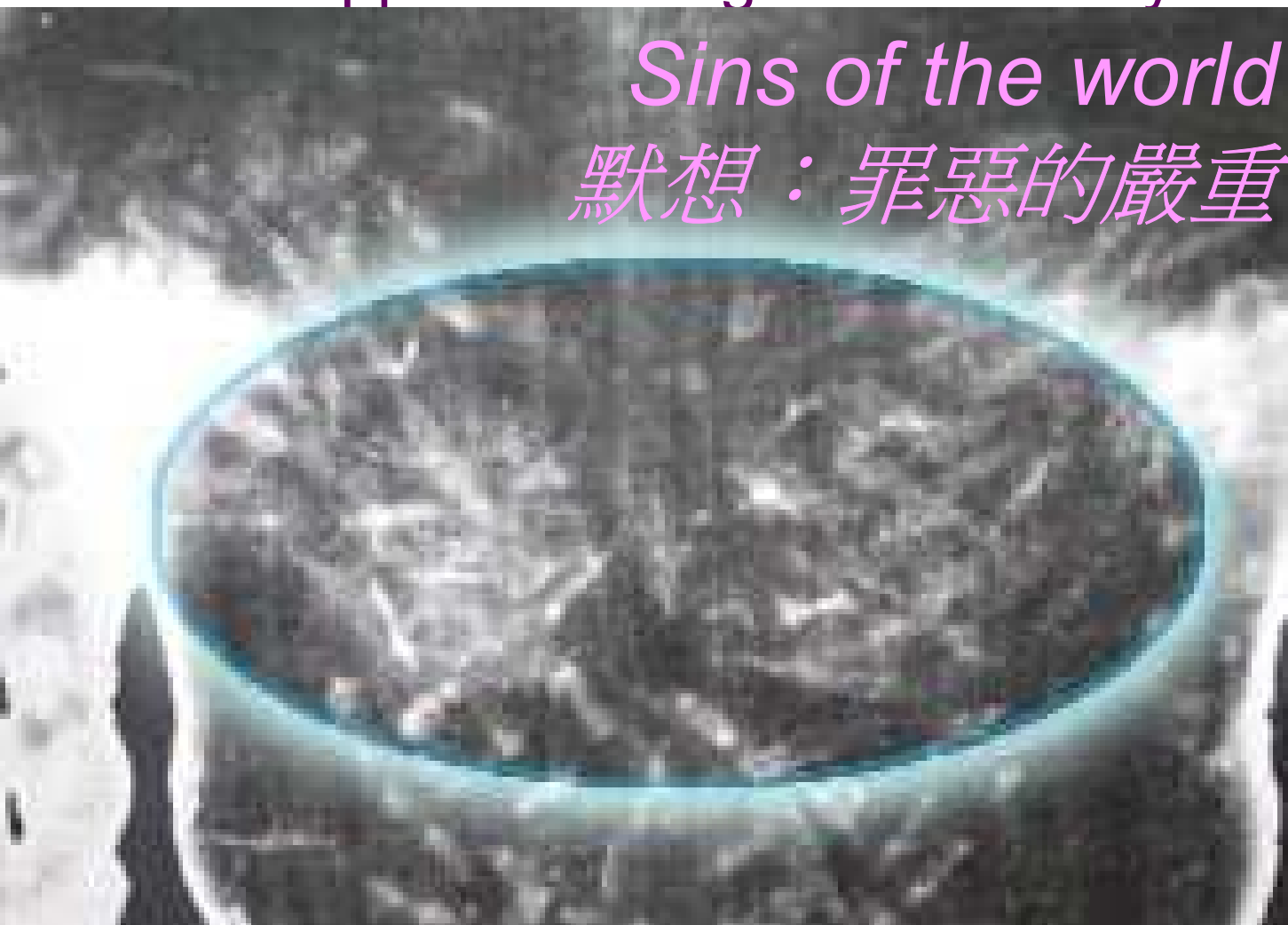- ◆ 30 pierced wounds have been identified so far
- ◆ Crown of thorns was not a ring weaved of thorns, but covers the entire top of the head like a cap



Back: wounded in large area of the shoulder,  
appears having carried heavy and rough object

*Sins of the world*  
默想：罪惡的嚴重

◆ So they took Jesus, and carrying the cross himself he went out to what is called the Place of the Skull, in Hebrew, Golgotha. (John 19:16-17)





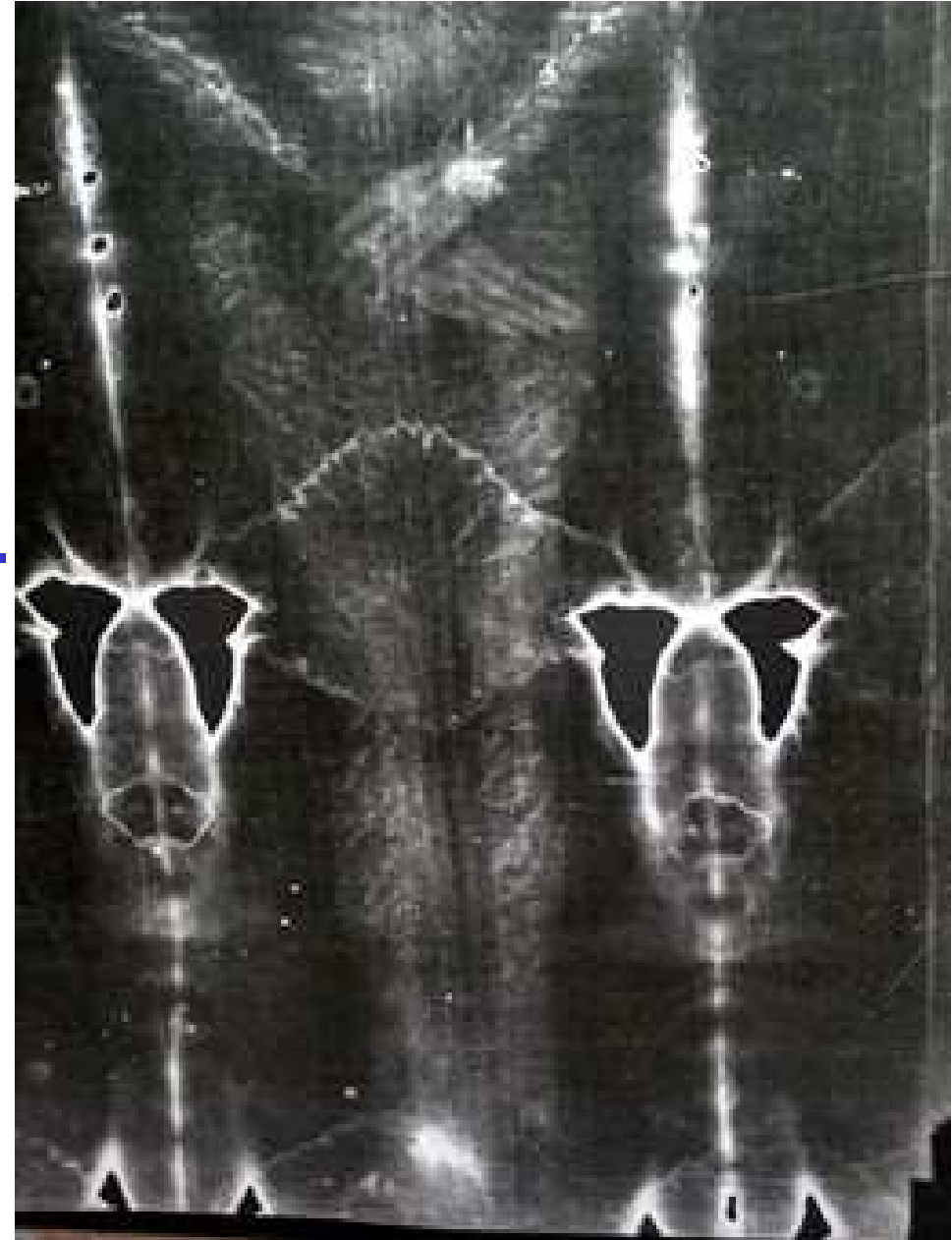
## Fall

- ◆ The nose is broken and soil is found there. It may have resulted from falling with both hands tied to the wood of the cross he's carrying.



## Knee injury

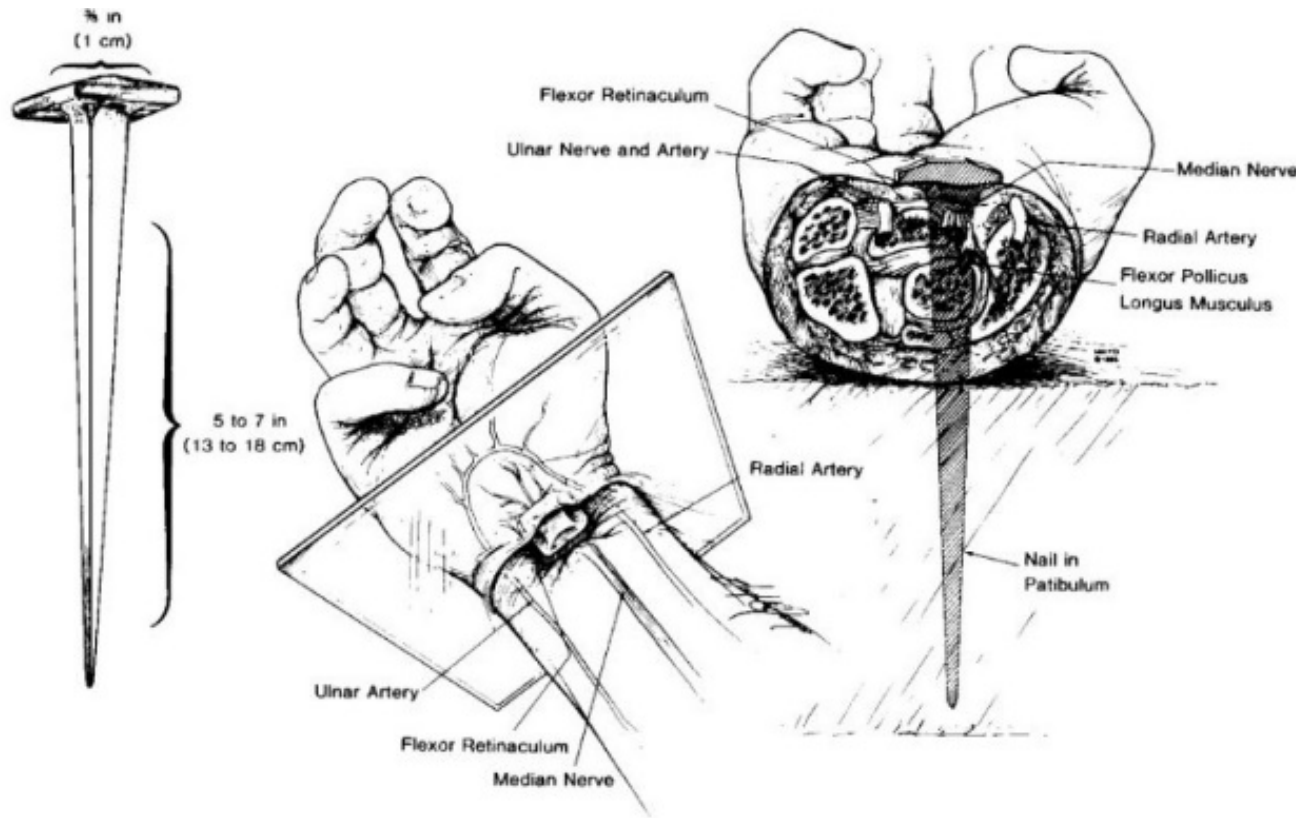
- ◆ Both knees, especially the left, are injured seriously and are soiled, as would have been caused by falling.
- ◆ Composition of soil at the broken nose and the knee consistent with those in Jerusalem



## medical research: nailing in the wrist, not the palm

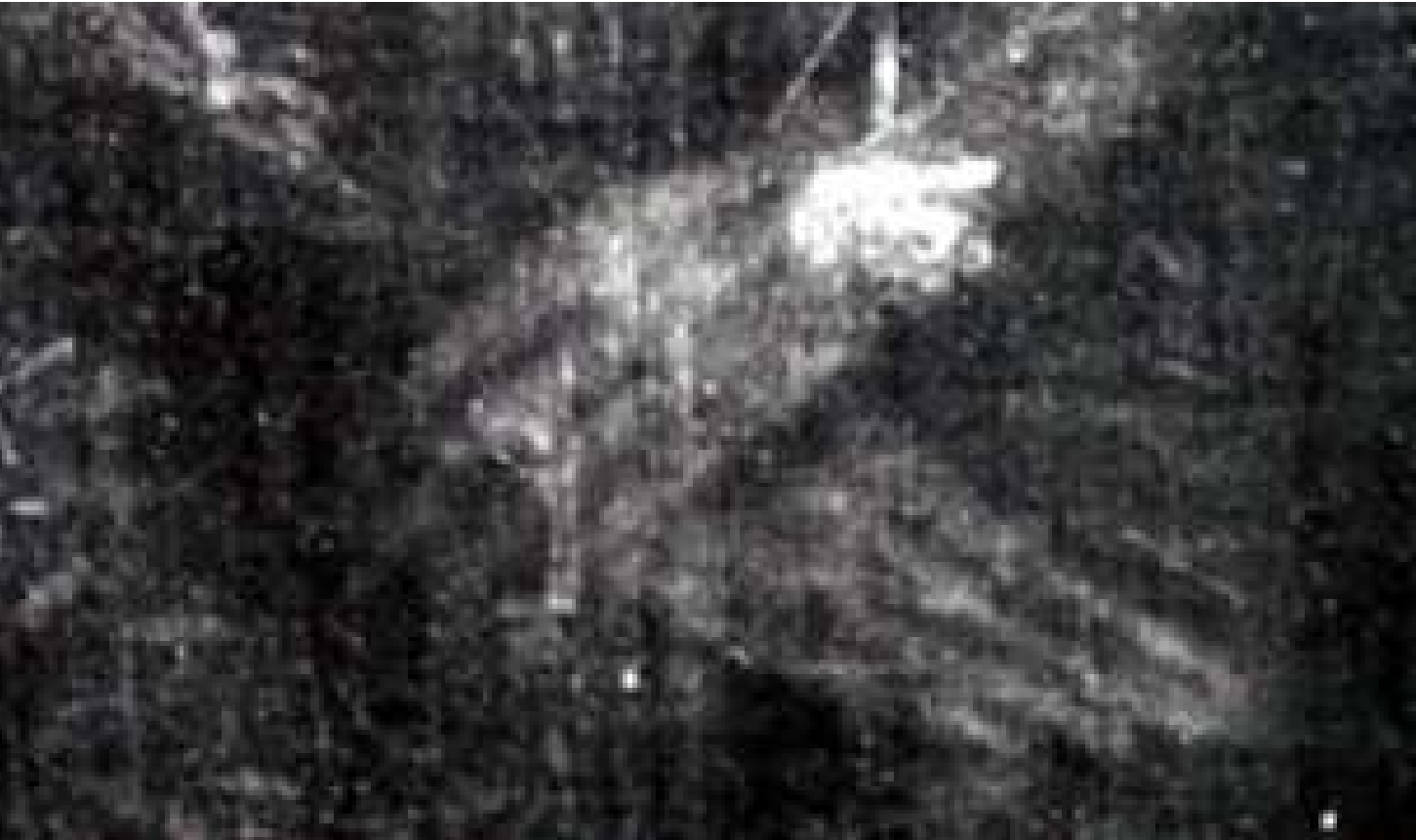Pierre Barbet, M.D., "A Doctor at Calvary," 1953

- ◆ In 1950, Pierre Barbet, MD, published a book which says that nailing at the wrist is necessary to support the body weight, thus correcting the traditional crucifixion pictures





Only 4 fingers stretch out



- ◆ The central nerve of the hand passes here, resulting in excruciating pain that the thumb will bend inward

Hands nailed on the wrist;  
Both legs bleed with pierced wound at ankle

*Misuse the gift of freedom  
to sin*

默想：誤用自由的恩寵  
去犯罪

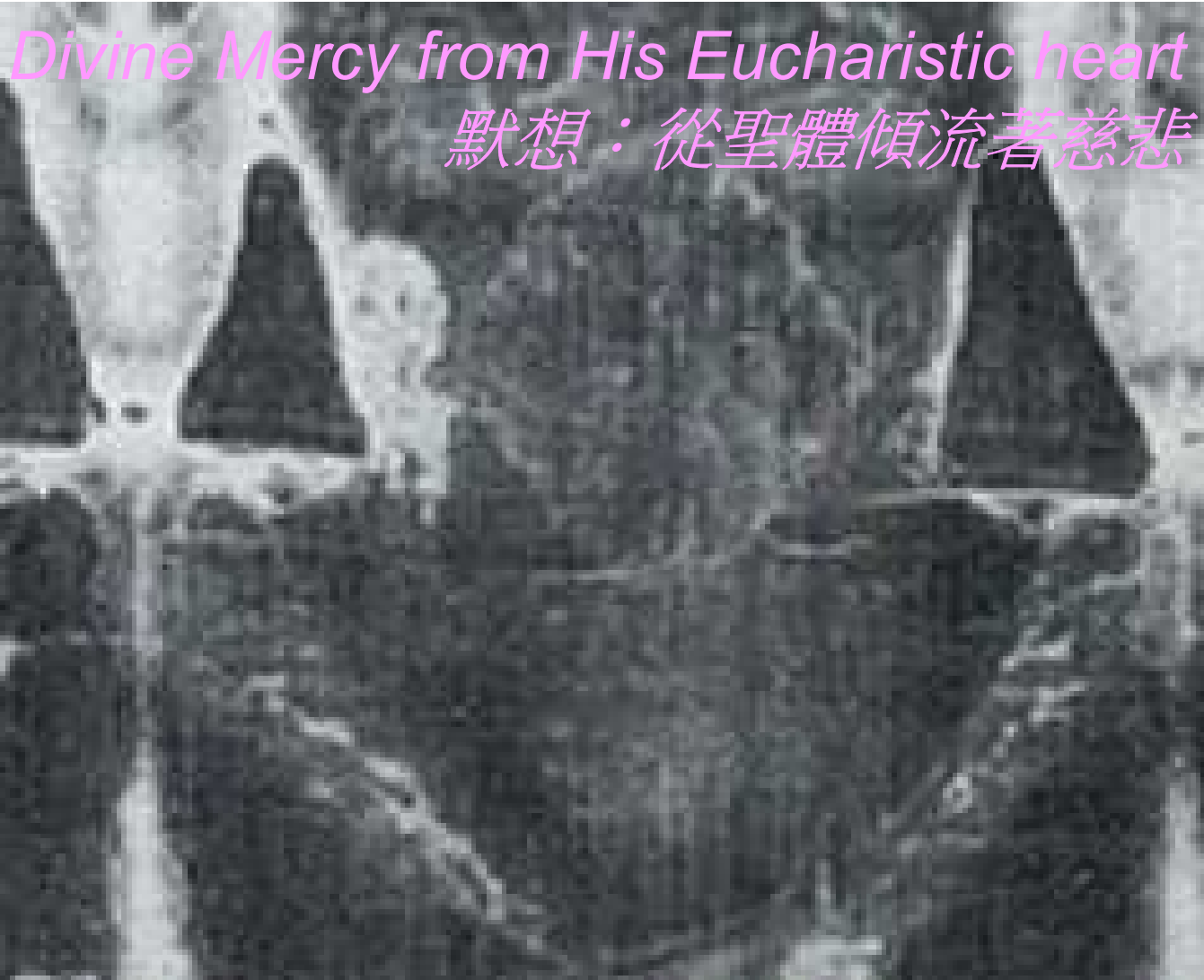*Jesus forfeited freedom  
on the cross*

*Continues to forfeit freedom  
in the blessed host*

默想：主在十字架上喪失自由  
繼續謙卑在喪失自由的麵酒形中

Front: pierced at the right side

Pierre Barbet, M.D., "A Doctor at Calvary," Chap 7: The wound to the heart, 1953



- ◆ Large wound between 5th and 6th rib, and large amount of blood and water flow out
- ◆ suggesting deep lance wound
- ◆ pericardium - serum,
- ◆ vena cava - blood